

Secondary Anetoderma Associated with Mastocytosis

Dimitris Kalogeromitros^a Stamatis Gregoriou^b Michalis Makris^a
Sofia Georgala^b Duraisamy Kempuraj^c Theoharis C. Theoharides^c

^aDepartment of Allergy, 'Attikon' Hospital, University of Athens, and ^bDepartment of Dermatology, 'A. Sygros' Hospital, University of Athens, Athens, Greece; ^cDepartment of Pharmacology and Experimental Therapeutics, Tufts University School of Medicine and Tufts-New England Medical Center, Boston, Mass., USA

© Free Author Copy - for personal use only

PLEASE NOTE THAT ANY DISTRIBUTION OF THIS ARTICLE WITHOUT WRITTEN CONSENT FROM S. KARGER AG, BASEL IS A VIOLATION OF THE COPYRIGHT.

Upon request a written permission to distribute the PDF file will be granted against payment of a permission fee depending on the number of accesses required. Please contact Karger Publishers, Basel, Switzerland at permission@karger.ch

Key Words

Anetoderma · Collagen · Mastocytosis · Urticaria pigmentosa

Abstract

Background: Mastocytosis represents a wide spectrum of proliferative disorders of mast cells in the bone marrow, skin and/or internal organs. The most common manifestation is urticaria pigmentosa (UP), which is characterized by small or large brown-red maculopapules on the skin. Occasionally, elastic and collagen fibers in the lesions degenerate and result in a lax area of skin termed anetoderma. **Methods:** We report a 21-year-old male patient with multiple cutaneous anetodermic lesions, present since infancy, at UP sites confirmed with histochemistry. **Results:** Urinary N-methyl 24-hour histamine levels were elevated, but serum tryptase levels were within normal limits. Radiologic examination of long bones was unremarkable, as well as all other blood results. UP biopsy showed absence of epidermal involvement and increased number of mast cells located perivascularly. There was fragmentation of elastic fibers in the papillary dermis. **Conclusions:** A patient with multiple cutaneous anetodermic lesions, presented since infancy, led to the diagnosis of UP. Such an association is rare and raises intriguing questions concerning the pathogenesis of anetoderma.

Copyright © 2007 S. Karger AG, Basel

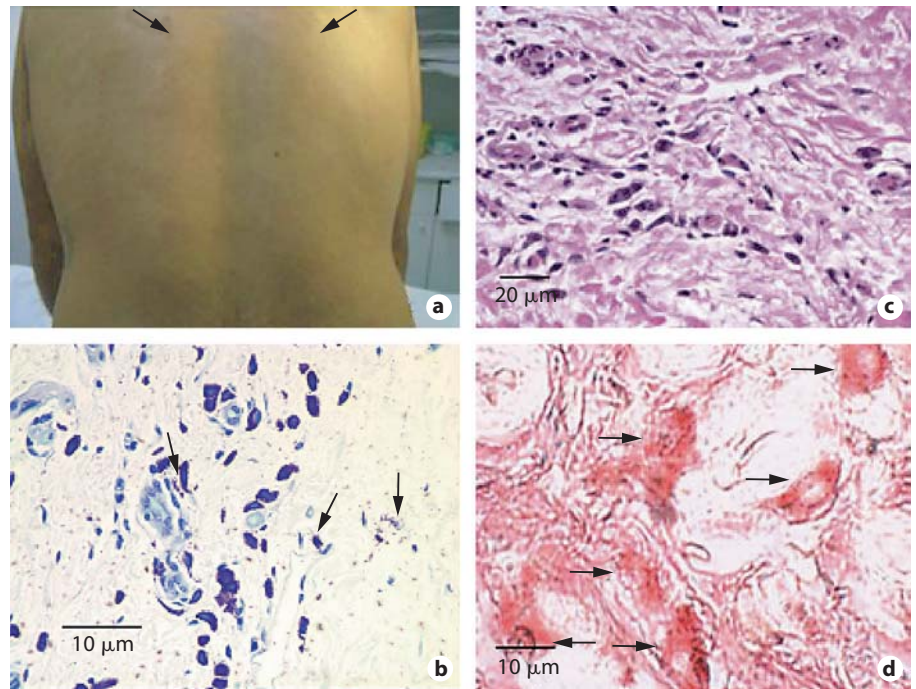
Introduction

Mastocytosis represents a wide spectrum of proliferative disorders of mast cells in the skin and/or internal organs [1, 2]. The most common manifestation is urticaria pigmentosa (UP), which is characterized by small or larger brown-red maculopapules on the skin. Occasionally, elastic and collagen fibers in the lesions degenerate, resulting in a lax area of skin, termed anetoderma [3]. We report a patient with multiple cutaneous anetoderma lesions, presented since infancy. The precise triggers that lead to mast cell secretion of tissue matrix degenerative enzymes is unknown.

Patient

A 21-year-old man was referred to our outpatient department with multiple atrophic macules of wrinkled skin, involving the torso and arms (fig. 1a). Upon palpation, the lesions could be depressed deeply without resistance, unlike the surrounding normal-colored skin. The patient's mother reported development of reddish-brown pruritic papules on the shins bilaterally when he was 3 months old. They gradually expanded to involve the whole torso and extremities by the age of 5 months. The brownish papules faded by the age of 12 months and never flared up again, leaving the residual macules the patient presented on examination. Stroking these lesions resulted in mild wheal development. He presented with allergic rhinitis and asthma at the age of 15, as well

Fig. 1. a Anetodermic lesions on the patient's back (arrow). Photomicrographs of affected skin showing increased number of cells located perivascularly by Giemsa (**b**), containing metachromatic granules stained with toluidine blue (**c**, arrows indicate particularly degranulated mast cells), and immunohistochemical staining for tryptase with mouse antihuman tryptase monoclonal antibody (1 $\mu\text{g}/\text{ml}$, Chemicon, Temecula, Calif., USA) by alkaline phosphatase-anti-alkaline phosphatase procedure (Dako Cytomation APAAP Kit System, Carpinteria, Calif., USA) (**d**, arrows indicate degranulated mast cells). Negative control performed by omission of the primary antibody or by using an isotype-matched mouse IgG1 antibody instead of the primary antibody did not show positive staining (not shown).



as Raynaud's phenomenon on the hands. His family history was unremarkable.

There was no organomegaly, lymphadenopathy or other abnormalities in the physical examination. Complete blood count, routine biochemical tests, erythrocyte sedimentation rate, urine analysis, serum protein electrophoresis, C-reacting protein and antinuclear antibody titers were within normal limits. Urinary 24-hour N-methyl histamine levels were elevated (272 $\mu\text{mol}/\text{mol}$ creatinine). Radiologic examination of the long bones was unremarkable.

Tryptase in the serum was assayed by using the Unicap 100 automated unit from Pharmacia & Upjohn (Uppsala, Sweden) [4] and the tryptase level was 5.4 $\mu\text{g}/\text{ml}$. IL-6 levels in the serum were assayed by ELISA using a kit from R&D Systems (Minneapolis, Minn., USA) and were below the detection level; the minimum detectable level of IL-6 using this kit was 0.7 pg/ml.

A punch biopsy from the lesions was made and paraffin sections (8 μm) were cut for staining. Histology revealed the absence of epidermal involvement and increased number of cells located perivascularly. These appeared to be mast cells by Giemsa staining (fig. 1b) and were confirmed as mast cells since they contained metachromatic granules as demonstrated by toluidine blue staining (fig. 1c) and were positive for tryptase (fig. 1d); some of these mast cells were partially degranulated.

The sections were deparaffinized and stained for mast cell tryptase by the alkaline phosphatase antialkaline phosphatase (APAAP) procedure using the Dako APAAP Kit system (Dako Cytomation, Carpinteria, Calif., USA) as reported previously [5]. There were numerous cells stained by tryptase and they also appeared mostly intact (fig. 1d).

Van Gieson stain showed diminution and fragmentation of elastic fibers in the papillary dermis (not shown).

Electron microscopy of the patient's healthy skin did not reveal any inherent defect in the elastic and collagen fibers that might predispose to fragmentation. A diagnosis of secondary anetoderma associated with UP was made based on the clinical, laboratory and histological findings.

Congo red did not reveal any accumulation of amyloid perivascularly (not shown). Serum protein electrophoresis, immunoelectrophoresis and urinalysis for Bence-Jones proteins was unremarkable. Since the patient did not report any symptoms of systemic mastocytosis (SM), we did not consent to a bone marrow biopsy; however, the possibility of SM remains open. No treatment was initiated, but since SM could not be ruled out, the patient was asked to return at 6 months. At that time, he was disease free and was advised to return every 6 months for the next 5 years.

Discussion

The term anetoderma derives from the Greek word 'anetos' meaning relaxed and has been used to describe a localized laxity of the skin. Anetoderma can be either primary or secondary to an inflammatory dermatosis, such as syphilis, tuberculosis, lupus erythematosus, perifolliculitis, macular atrophy, lymphocytoma cutis, xanthoma, pilomatrixoma, nodular amyloid, systemic administration of penicillamine and mastocytosis [6]. Secondary anetoderma associated with mastocytosis has been sparsely reported in the medical literature [3, 7–9].

Nevertheless, this presentation is not included in the comprehensive classification of mastocytosis [10].

Pathogenesis of the degeneration of the collagen and elastic fibers observed in anetodermic cutaneous lesions is poorly understood. However, the mast cell has been suggested to play a significant part in the degenerative process. Mast cell-derived mediators have been reported to inhibit enzymes involved in collagen synthesis impeding the hydroxylation and glycosylation of the polypeptide chain [11]. Heparin has also been shown to increase fragmentation of collagen fibers [12]. Secretion of proteolytic enzymes such as chymase and tryptase could also weaken the tissue matrix. Furthermore, the accumulation of eosinophils, neutrophils and macrophages due to the release of the respective chemotactic agents during mast cell degranulation has been suggested to promote elastase activity, resulting in fragmentation of the elastic fibers [13].

Secondary anetoderma has been observed in only a few patients with UP. One would, therefore, have to consider whether genetic predisposition in certain individuals makes collagen and elastic fibers more susceptible to the degenerative process initiated by mast cell mediators. Moreover, lesions develop in some, but not all, sites of UP. It is likely that local mast cells express a unique mutation leading either to selective or overt release of pigment- and tissue-degrading molecules. Quantitative and qualitative variations in the mediators released locally might account for the site and/or patient predilection in the development of anetoderma. RT-PCR of affected skin for target enzymes may shed some light not only on the pathogenesis of anetoderma, but also on the possible mechanism that has kept UP quiet in this patient. For instance, recent investigation of skin biopsies from chronic urticaria lesions revealed increased expression of histidine decarboxylase and corticotropin-releasing hormone that may explain stress-induced exacerbations [14].

References

- 1 Castells M, Austen KF: Mastocytosis: mediator-related signs and symptoms. *Int Arch Allergy Immunol* 2002;127:147–152.
- 2 Akin C, Metcalfe DD: Systemic mastocytosis. *Annu Rev Med* 2004;55:419–432.
- 3 Venencie PY, Winkelmann RK, Moore BA: Anetoderma: clinical findings, associations and long-term follow-up evaluations. *Arch Dermatol* 1984;120:1032–1039.
- 4 Kempuraj D, Huang M, Kandere K, Boucher W, Letourneau R, Jeudy S, Fitzgerald K, Spear K, Athanasiou A, Theoharides TC: Azelastine is more potent than olopatadine in inhibiting interleukin-6 and tryptase release from human umbilical cord blood-derived cultured mast cells. *Allergy Asthma Immunol* 2002;88:501–506.
- 5 Kempuraj D, Papadopoulou N, Stanford EJ, Christodoulou S, Madhappan B, Sant GR, Solge K, Adams T, Theoharides TC: Increased numbers of activated mast cells in endometriosis lesions positive for corticotropin-releasing hormone and urocortin. *Am J Reprod Immunol* 2004;52:267–275.
- 6 Thivolet J, Cambazard F, Souteyrand P, Pierini AM: Mastocytosis evolving into anetoderma: review of the literature. *Ann Dermatol Venereol* 1981;108:259–266.
- 7 Carr RD: Urticaria pigmentosa associated with anetoderma. *Acta Derm Venereol* 1971;51:120–122.
- 8 Thivolet J, Pierini AM, Cambazard F, et al: Cutaneous mastocytosis with secondary anetoderma and cicatricial alopecia associated with a valve disease. *Ann Dermatol Venereol* 1981;108:269–275.
- 9 Gebauer KA, Navaratnam TE, Holgate C: Pruritic pigmented papules posing permanent problems: urticaria pigmentosa with secondary anetoderma. *Arch Dermatol* 1992;128:107–110.
- 10 Valent P, Horny H, Escribano L, Longley BJ, Li CY, Schwartz LB, Marone G, Nunez R, Akim C, Sotlar K, Sperr WR, Wolff K, Brunning RD, Parwaresh RM, Austen KF, Lennert K, Metcalfe DD, Vardiman JW, Bennett HM: Diagnostic criteria and classification of mastocytosis: a consensus proposal. *Leukemia Res* 2001;25:603–625.
- 11 Myllyla R, Seppa H: Studies on enzymes of collagen biosynthesis and the synthesis of hydroxyproline in macrophages and mast cells. *Biochem J* 1979;182:311–316.
- 12 Degos R, Cottenot F: Heparine and collagen. *Bull Soc Fr Derm Syph* 1953;60:229–230.
- 13 Uitto J: Biochemistry of the elastic fibers in normal connective tissues and its alterations in disease. *J Invest Dermatol* 1979;72:1–10.
- 14 Papadopoulou N, Kalogeromitros D, Staurianean NG, Tiblalex D, Theoharides TC: Corticotropin-releasing hormone receptor-1 and histidine decarboxylase expression in chronic urticaria. *J Invest Dermatol* 2005;125:952–955.

© Free Author Copy - for personal use only

PLEASE NOTE THAT ANY DISTRIBUTION OF THIS ARTICLE WITHOUT WRITTEN CONSENT FROM S. KARGER AG, BASEL IS A VIOLATION OF THE COPYRIGHT.

Upon request a written permission to distribute the PDF file will be granted against payment of a permission fee depending on the number of accesses required. Please contact Karger Publishers, Basel, Switzerland at permission@karger.ch